



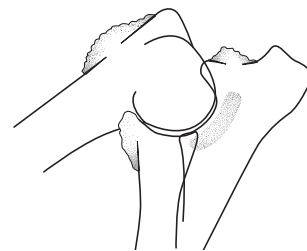
Elbow dysplasia in dogs

Revised by Gary Clayton Jones BVetMed DSAO DVR FRCVS
with additional graphics by Jonathan Clayton Jones



The British Veterinary Association and The Kennel Club
— working together for excellence in canine health

Elbow dysplasia has been identified as a significant problem in many breeds. Importantly, the condition appears to be increasing worldwide. It begins in puppyhood, and can affect the dog for the rest of its life



The 'flexed mediolateral' view is a side-on view of the elbow. This view allows examination of the secondary changes in ED which occur in the shaded areas. Note how some of the shaded areas here are overlaid by other structures, which makes them difficult to examine

Veterinary surgeons have been aware for many years of a number of conditions that begin in puppies and cause lameness. Hip dysplasia was the first such disease to be widely recognised and a scheme for its assessment and control is well established in the UK. Elbow dysplasia (ED) is a significant problem in many breeds worldwide, and although it begins in puppyhood it can continue to affect the dog for the rest of its life.

The principal cause of ED lies in the genetic makeup of the animal. Therefore, a scheme that screens animals for elbow abnormalities will allow animals with the best elbow joints to be chosen for breeding, and will help to reduce the level of the problem in the canine population.

Elbow dysplasia—the disease

ED simply means 'abnormal development of the elbow'. The term includes a number of specific abnormalities that affect different sites within the joint. These cause problems by affecting the growth of the cartilage which forms the surface of the joint or the structures around it. These abnormalities are primary lesions, which then induce a secondary osteoarthritic process. The most common primary lesions are:

- Fragmented or ununited medial coronoid process (FCP)
- Osteochondritis dissecans (OCD or OD)
- Ununited anconeal process (UAP)

There are other, rarer, primary lesions that may occur in combination with these or on their own. Primary lesions begin early during the growth of the puppy, and are commonly present in both elbows to some extent.

Once the dog reaches skeletal maturity the primary lesions may stabilise. However, once abnormal development has started with a primary lesion, further secondary changes follow, in particular, abnormal wear of the joint surfaces and osteoarthritis (sometimes termed arthrosis, or degenerative joint disease—DJD). The secondary lesions cannot be reversed and remain a potential problem for the rest of the dog's life.

The elbow is particularly vulnerable to this type of disease. The joint resembles a hinge in which the bones and cartilage forming each side of the joint have complex shapes that fit together closely. The elbow has a wide range of joint movement and normal foreleg gait is more dependent on the elbow than the other joints. Thus, a small change in the shape of one part of the joint can have major consequences for the joint function, like a small piece of grit in a door hinge. Once elbow function is affected, foreleg gait becomes altered.

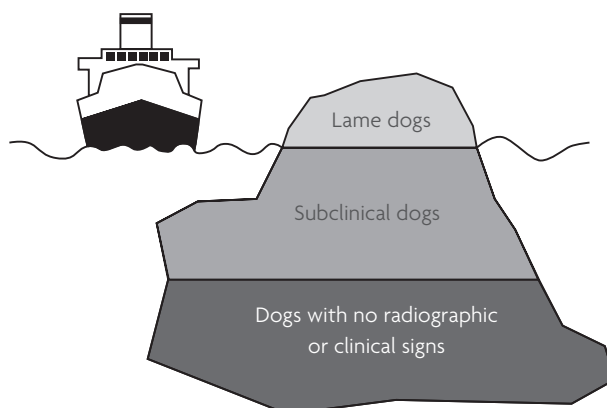
An additional problem with ED is that lame dogs are only the tip of the 'disease iceberg'. Many dogs have subclinical disease in that they have primary lesions or osteoarthritis

in their elbows but do not appear obviously lame. Some dogs will be symmetrically lame in each foreleg, which can be very difficult to see. Fortunately, these subclinical dogs can often be identified by taking radiographs (X-ray images) of their elbows. Even though they appear to show no lameness themselves, they have a high chance of producing lame offspring if they breed.

Causes of elbow dysplasia

ED is a multifactorial disease, which means that a number of factors can influence the occurrence of the condition. The most important factor, however, is the genetic makeup of the dog. Other factors such as growth rate, diet and level of exercise may influence the severity of the disease in an individual dog, but they cannot prevent the disease or reduce the potential of the dog to pass on the disease to offspring. However, studies show that ED has a high heritability confirming that a high proportion of the disease is genetic.

As the individuals of each breed of



Dogs in which elbow dysplasia caused lameness are only the 'tip of the iceberg'. These animals are obvious because of their lameness. However, there are many dogs with subclinical disease that have an increased risk of producing offspring with elbow dysplasia. These animals are not obvious and can only be detected by screening

dog have a proportion of their genetic makeup (genotype) in common, it is not surprising that some breeds are more vulnerable to a heritable condition than others. In general, medium and large breed dogs are considered to be most vulnerable to ED, although the condition has been found in some smaller breeds.

Unfortunately, ED is not controlled by a single gene or a simple inheritance. It is a polygenic characteristic, which means that it is controlled by the combination of many gene variants. One way of visualising this is to think of a 'normal' dog as carrying a few of the gene variants that can cause elbow problems. A dog with subclinical disease will have more of these problem gene variants, and a lame animal will have a higher proportion still.

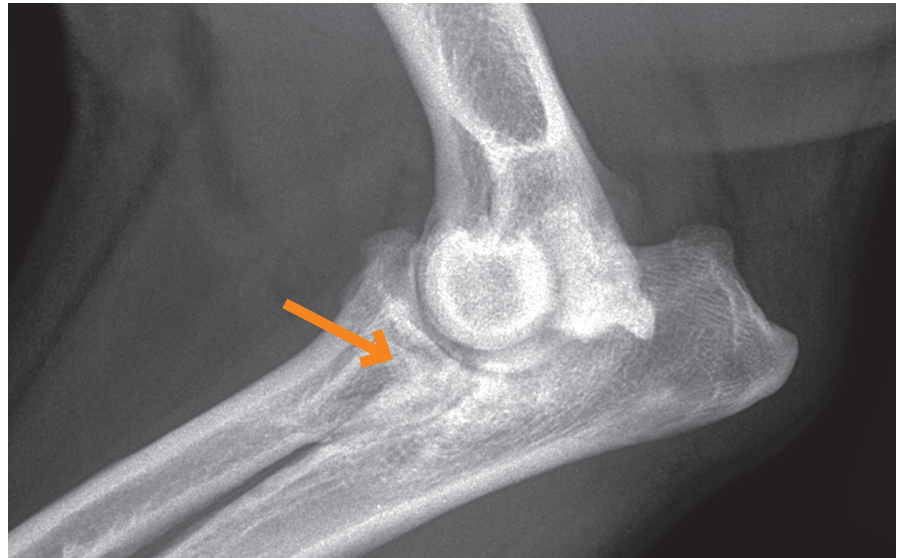
Control of elbow dysplasia

As the genotype is the overwhelming influence in the cause of ED, the disease can be controlled by minimising the problem of gene variants within the population. This means selecting sires and dams with the best genotype. As yet there is no laboratory test on blood or other tissue samples to enable us to select the best genotype. However, dogs can be screened reasonably effectively by radiographing (X-raying) the elbows and looking for the signs of ED.

If sires and dams are only selected from animals with no or minimal ED, most of the clinical and subclinical animals can be eliminated from the breeding programme, and so prevent them passing on their defective genetic makeup to the next generation. The success of such screening depends on a high proportion of the breed participating and making the information public so that low-risk animals can be selected for breeding. There are international guidelines for screening schemes administered by the International Elbow Working Group (IEWG), which encourages a coordinated approach to the problem through regular meetings.

The UK elbow dysplasia scheme

The Canine Health Schemes (CHS) is an association between the British Veterinary Association (BVA) and The Kennel Club (KC) to run a screening scheme along IEWG guidelines. Initially, schemes were run by individual breed groups such as the Bernese Mountain Dog Club of Great Britain and the Guide Dogs for the Blind Association, which were successful in reducing the incidence of ED.



Primary lesion: abnormal medial coronoid process of the ulna (arrowed). This area of bone is flattened and irregular; compare with the normal elbow radiograph overleaf. Elbow osteoarthritis is also present

The grading procedure

Although a number of different views have been suggested, two radiographic views of each elbow joint are now taken as described on page 4.

This ensures that most areas of the joint where abnormalities can be detected can be examined. The radiographs are examined by two scrutineers who look for primary lesions and any signs of osteoarthritis. A grade is then given for each elbow, based on the presence of primary lesions and the size and extent of the secondary lesions. The overall grade is determined by the higher of the two individual grades. Grades for each elbow are not added together as they are for the two hips in the HD Scheme. Identification of subclinical disease and its grade in either elbow is the important factor in screening, so the grade of the worse elbow is always quoted as the overall grade and is published on the progeny's Kennel Club registration documents and in The Kennel Club Breed Records Supplement.

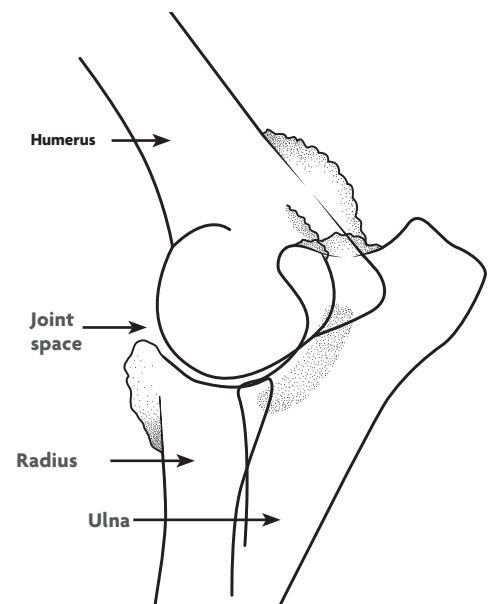
The grading procedure and the records are under continuous review and discussed at the annual CHS scrutineers' meeting, to enable changes in procedure to be made in light of new orthopaedic research, as well as enabling publication of information for interested parties such as dog breeders and geneticists.

Costs

The owner is liable for their veterinary surgeon's fee for anaesthetising the dog and taking the radiographs, as well as the CHS' fee for the grading.

Some common breeds at risk are:

Basset Hound, Bernese Mountain Dog, Dogue de Bordeaux, German Shepherd Dog, Great Dane, Irish Water Spaniel, Irish Wolfhound, Large Munsterlander, Mastiff, Newfoundland, Otterhound, Golden Retriever, Labrador Retriever, Rottweiler, St Bernard



The 'extended mediolateral' view permits visualisation of some of the shaded areas obscured by the 'flexed mediolateral' view. In this view, the position of the joint is similar to that in the standing dog

The ED grading system is simple:

- 0 = Radiographically normal
- 1 = Mild osteoarthritis (OA)
- 2 = Moderate or a primary lesion with no OA
- 3 = Severe OA or a primary lesion with OA

For further details see
www.bva.co.uk/chs

Advice on breeding

The overall grade is used internationally as the basis for breeding advice. Ideally dogs with 'normal' (grade 0) elbows should be chosen and certainly dogs with 2 or 3 arthrosis should not be used for breeding.

As ED is a prevalent disease, especially in the breeds listed on page 3, such advice will only be effective if it is continued over a number of generations. The most difficult part of accepting such advice for many breeders is that some dogs have never been lame and exercise freely, but nevertheless may have high grades. This is the subclinical population with the ability to pass on the problem in the breed. For long-term control of the disease these dogs ought not to be bred from.

Treatment of clinical ED

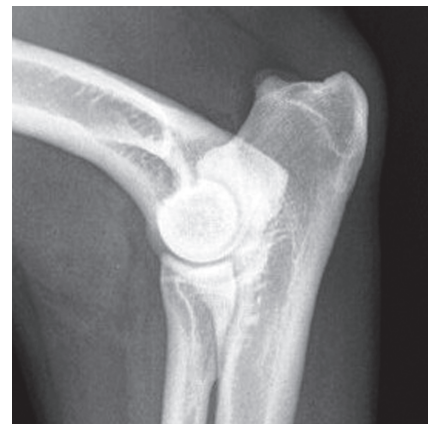
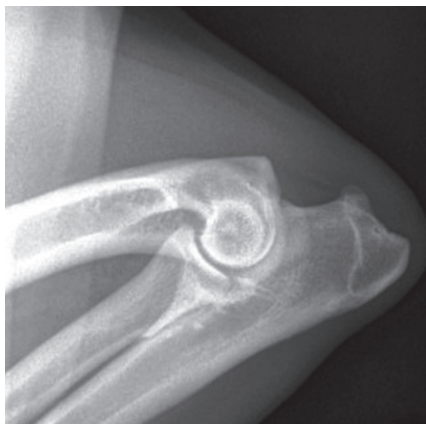
Dogs that have clinical ED often become lame between six and 12 months of age. Initially the lameness may be difficult to ascribe to a particular joint. However, at this age a persisting lameness should be investigated by a veterinary surgeon, as other conditions may lead to similar signs.

Diagnosis is normally based on lameness with pain found on flexion and extension of the elbow joint as well as joint enlargement. The animal may have a short or stilted gait as both limbs are often affected. Confirmation of the diagnosis is made by finding primary or secondary lesions on radiographs of the elbow, or by other investigations such as CT or arthroscopy.

Treatment methods vary depending on the nature and severity of the problem. Conservative treatment involving weight restriction and control of exercise is always important. Drugs may be used to relieve pain and inflammation, and may promote repair processes within the joint.

In some dogs, surgery to remove fragments of cartilage and bone from the joint may be advised but this may not always be appropriate. In nearly all cases there will be some secondary changes which lead to further problems in the joint, and may gradually progress throughout the dog's life and may restrict the dog's ability to exercise.

However, most dogs will be comfortable with a fair level of exercise if treated carefully during growth between six to 18 months of age. In severe cases it may be necessary to consider more major surgery.



Radiographs of a normal elbow. These views show the clean lines and lack of secondary change which characterise a normal joint

Getting a dog's elbows graded

Owners should contact their veterinary surgeon and arrange an appointment for their dog to be radiographed (X-rayed). The radiographs must be taken under anaesthesia or heavy sedation so the dog may have to be left at the veterinary practice. Elbow radiographs can be taken at the same time as those for the CHS Hip Dysplasia Scheme. When taking the dog for its radiographs owners should remember the following.

- The dog must be at least one year old, but there is no upper age limit.
- The dog must be permanently and uniquely identified by way of a microchip or tattoo.
- The dog's KC registration certificate and any related transfer certificates must be available so that the appropriate details can be printed on the radiographs.
- Microchip/tattoo numbers must also be printed on the radiographs.

- Radiographs of non-registered dogs may also be submitted to the ED scheme.
- The owner should sign the declaration (first part) of the certificate, to verify the details are correct and grant permission for publication of the results.

Once the radiographs have been taken, the veterinary surgeon fills out the appropriate section of the certificate and submits both the radiographs and the certificate to the CHS. The results and the radiographs are normally returned to the veterinary surgeon within two weeks with the completed certificate for the owner and a copy for the veterinary surgeon. Once a grade has been given for a dog, the radiographs cannot be resubmitted. New radiographs can also not be submitted; however, owners have the right to an appeal which takes the form of a re-appraisal of the original radiographs. A letter of appeal must be made within 45 days of the date of the original certificate. The whole procedure from initial appointment to receiving the grades is handled through the submitting veterinary surgeon.

The Kennel Club has developed Estimated Breeding Values, or EBVs, a resource that allows breeders to estimate a dog's genetic risk of developing either hip or elbow dysplasia. For more information, please visit www.mateselect.org.uk.



There is a reduced fee when radiographs of the same dog are submitted simultaneously to the CHS for the Hip and Elbow Dysplasia Schemes.

For current fees and further information please contact:

Canine Health Schemes

7 Mansfield Street
London W1G 9NQ
Telephone 020 7908 6380
Email chs@bva.co.uk
www.bva.co.uk/chs

The Kennel Club

10 Clarges Street
London W1J 8AB
Telephone 0844 4633 980
hbs@thekennelclub.org.uk
www.thekennelclub.org.uk/doghealth