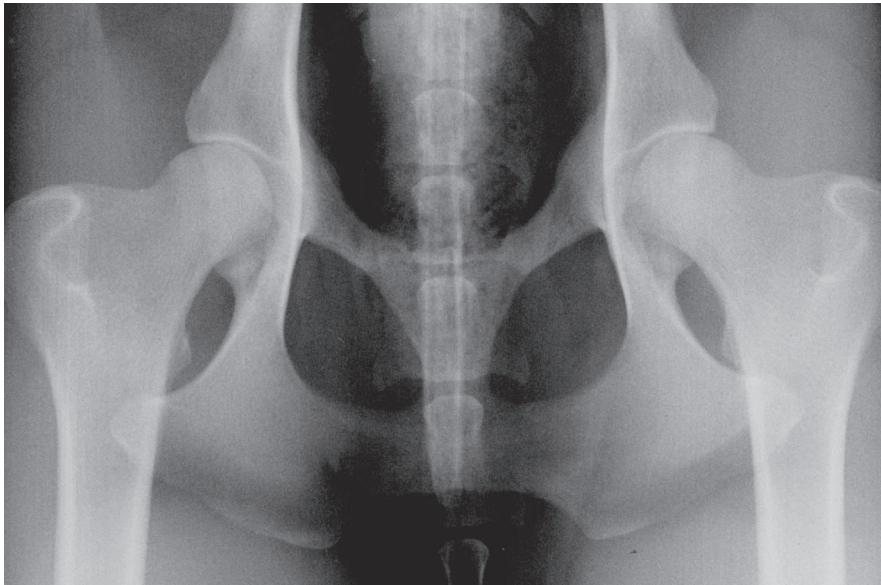




# Hip dysplasia in dogs



The British Veterinary Association and The Kennel Club  
— working together for excellence in canine health



**Radiograph of normal hips in a greyhound. The hip is a 'ball-and-socket' joint, the ball being the head of the thigh bone or femur, and the socket being part of the pelvis called the acetabulum. In good hips the femoral head is smoothly rounded and fits tightly and deeply into the acetabulum. The outlines of the bone are clear since there is no secondary osteoarthrosis. Compare this image with those of dysplastic joints below and on page 3.**

**H**ip dysplasia (HD) is a common inherited orthopaedic problem of dogs and a wide number of other mammals. Abnormal development of the structures that make up the hip joint leads to subsequent joint deformity. 'Dysplasia' means abnormal growth. The developmental changes appear first and because they are related to growth, they are termed primary changes. Subsequently these changes may lead to excessive wear and tear. The secondary changes may be referred to as (osteo)arthritis (OA), (osteo)arthrosis or degenerative joint disease (DJD).

Later one or both hip joints may become mechanically defective. At this stage the joint(s) may be painful and cause lameness. In extreme cases the dog may find movement very difficult and may suffer considerably.

It was in the light of this knowledge that the British Veterinary Association (BVA) and The Kennel Club (KC) developed a scheme some 50 years ago to assess the degree of hip deformity of dogs using radiography. To date radiographs (X-rays) from more than 250,000 dogs have been assessed providing a standardised reflection of the HD status of those dogs that have been examined. This information is primarily of use for breeders. Currently 175 breeds are surveyed by the scheme in the UK. Unregistered dogs and dogs from overseas are also eligible for assessment.

### Structure and function

The hip joints of land animals and even some birds are remarkably similar. Overall the design has withstood the test of time and is probably close to anatomical perfection. When athletic activity is required, the normal hip is an ideal means of transferring power

from the muscles to drive the body forwards with maximum strength and speed. It is the close relationship of the femoral head (ball) and acetabulum (socket) which enables rapid changes of direction. The entire hip joint is a unit comprising the bony structures contained within a joint capsule and supported by ligaments, tendons and muscles together with all their blood vessels and nerves. The large joint surfaces are lubricated by synovial fluid. The viscosity (oiliness) of this fluid ensures smooth, pain-free joint movement. It is not surprising that any variation from this ideal can have severe consequences.

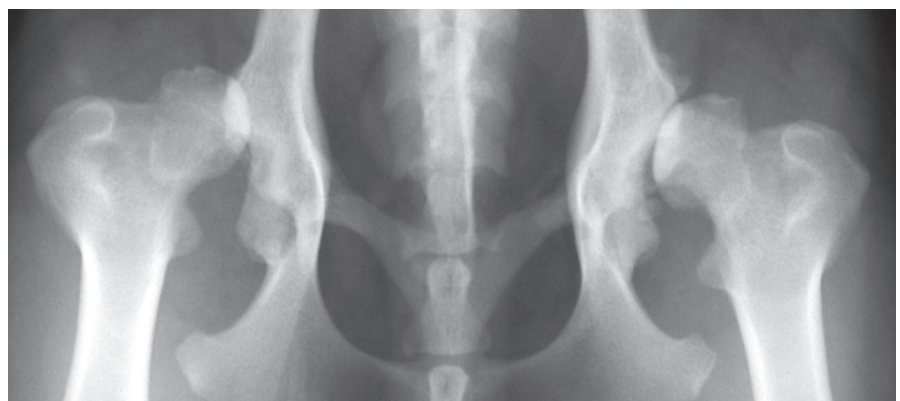### Developmental demands

It is argued that dogs are not born with hip joints already affected by dysplasia (unlike humans) but that any faults in development will tend to escalate with time, particularly during the rapid growth phase from about 14 to 26 weeks of age. However, changes begin as the very young puppy starts to become active and continue until the puppy is skeletally mature. Wear and tear of the

deformed joint results in varying amounts of inflammation and degeneration which lead to more deformity. This progressive deformation is sometimes referred to as remodelling. Some dogs may treble their size and body weight in just three months of adolescence so it is not surprising that there are many critical factors for the puppy at this stage. All the essential nutritional requirements for skeletal growth must be available in the right proportions and at the right time. The environment within which the dog is raised, including the type and intensity of exercise, growth rate and body weight are significant influences. However inheritance is a major factor and this is something which we are able to influence by the selection of breeding animals.

### Signs

As HD can include joint looseness (laxity), inflammation, pain, new bone formation and bone erosion, it may cause a range of observable signs from normal to minor changes in gait (in the mildly affected



**Severe hip dysplasia (total score 93). The right hip (on the left of the picture) has slipped out the socket (the acetabulum). This hip has dislocated because the socket is so shallow. The left hip (on the right of the picture) is just in the socket, but the socket is again very shallow and has been completely remodelled. Both hips are severely arthritic.**

cases) to obvious lameness, stiffness after rest and exercise intolerance and pain. As some individuals and breeds may be more stoical than others there is no way of estimating the severity of HD in any dog by observation alone. A veterinary surgeon's physical examination will provide a more reliable assessment by revealing limitation of joint movement, muscle wasting and pain in the joint(s). Usually a dog with HD does not demonstrate discomfort by yelping, as pain is likely to be dull and continuous rather than sharp and acute. The dog may, though, groan while resting or getting up.

Radiography is the only means of determining the presence or absence of HD. This is an X-ray examination to look at the relative shape and positions of the femoral head and acetabulum and the presence and degree of any secondary changes.

### Causes

It is known that two factors determine whether HD will occur, and if so, how bad it will be. These are hereditary and 'environmental' factors. 'Hereditary' relates to the genetic code passed to the offspring by both parents and environmental are all the outside influences which alter and shape the growth and functions of the bones, cartilage, ligaments, tendons and muscles of the body. In simple terms the genetic code is rather like an architect's plan (genotype), while the environment is like the builder and his materials (phenotype). In HD the architect has made some errors but the builders have a great influence on how things finally look and function.

### Treatment

It is possible to alleviate some or most of the signs of pain and limitation of movement caused by HD. Sophisticated medications and various surgical procedures are now available. Applied heat, massage, good bedding, exercise and weight management as well as nutrition and physiotherapy also play a part in caring for a dog affected by HD. Professional advice is always necessary to ensure that the best strategy is developed.

#### Some common breeds at risk:

- Labrador Retriever
- German Shepherd Dog
- Golden Retriever
- Rottweiler
- Bernese Mountain Dog
- Newfoundland

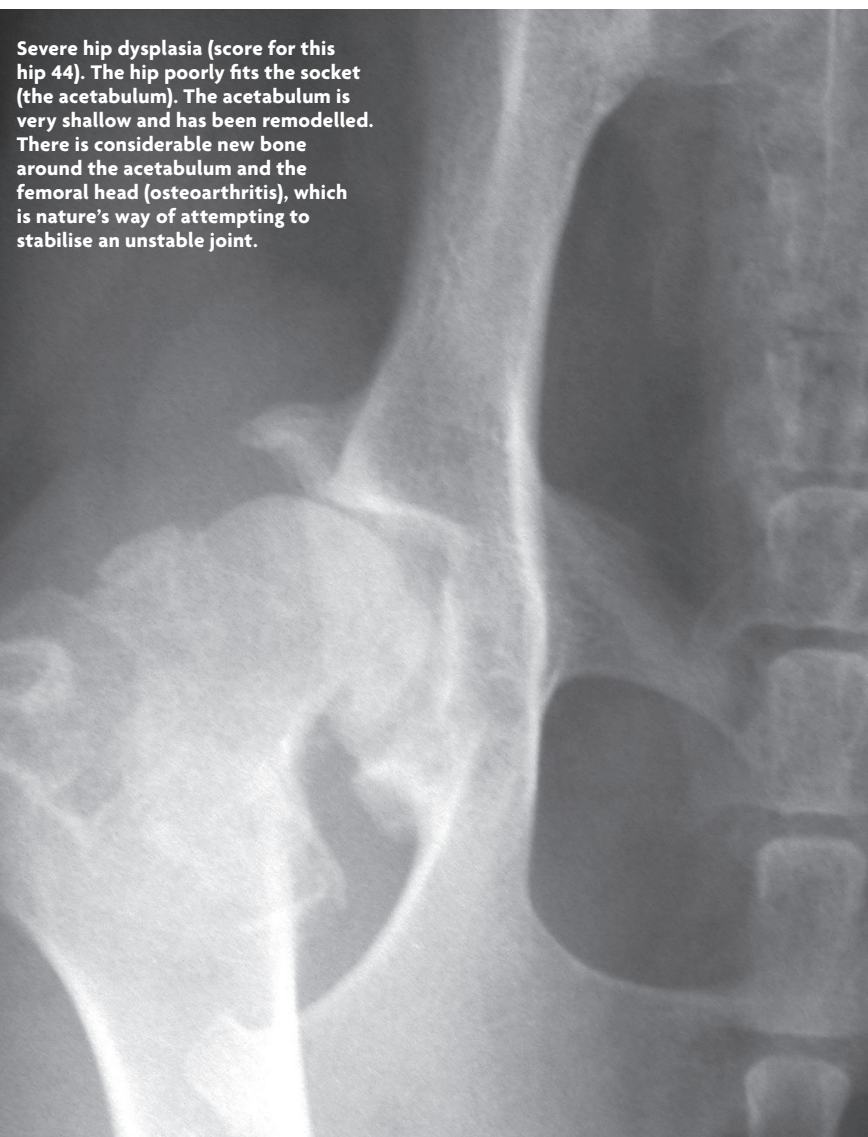
### The BVA/KC HD Scheme

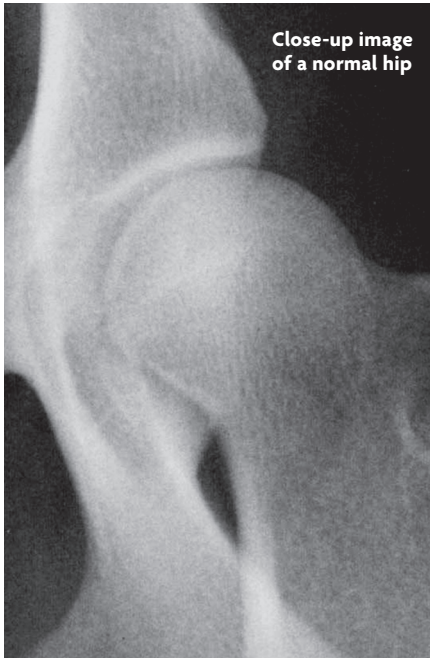All radiographs submitted to the BVA/KC Hip Dysplasia Scheme are 'scored'. The hip score is the sum of the points accrued for each of nine radiographic features in each hip joint. The lower the score the less the degree of HD present. The minimum (best) score for each hip is zero and the maximum (worst) is 53, giving a range for the total score of 0 to 106.

Sires (fathers) to be bred from should ideally be ones whose progeny (offspring) have achieved consistently low scores. The same selection procedure should be used for bitches for breeding, since the use of animals with greater than ideal scores will increase the risk of producing offspring with higher scores.

Failure to use the scoring system may give disappointing results but can also be potentially costly in terms of compromised breeding plans. It may lead to litigation, besides raising important animal welfare issues. For the hip scoring scheme to be meaningful and successful it is important that all potential breeding dogs are radiographed and that all radiographs taken under the scheme are submitted for scoring, whatever the apparent state of the hips. In addition, scoring of progeny, even if not intended for breeding, will provide much useful data for genetic analysis. This will ensure that the information gathered is as relevant as possible. It is only by this means that proper conclusions may be drawn by the scheme's statisticians, geneticists and veterinary advisers.

**For further information please visit [www.bva.co.uk/chs](http://www.bva.co.uk/chs)**





Close-up image of a normal hip

### Breed Specific Statistics and breeding advice

Hip scoring should be considered along with other criteria as part of a responsible breeding programme, and breeders should choose breeding stock with hip scores around and ideally below the breed median score. The median score is calculated from all the scores recorded for that breed over the previous five years and is the middle score of the population, i.e. 50% of dogs have a lower score and 50% have a higher score. It therefore represents the hip score of the 'average dog' in that breed and dogs with scores which are lower than the median have better than average hips for that breed. It is strongly recommended that hip scores of parents, grandparents, siblings and any previous progeny are considered as this gives the most accurate assessment of an individual dog's hip status.

**The Breed Specific Statistics and a more detailed explanation can be viewed at [www.bva.co.uk/chs](http://www.bva.co.uk/chs)**

### Getting a dog's hips scored

Owners should contact their veterinary surgeon and arrange an appointment for their dog to be radiographed (X-rayed). The radiographs must be taken under anaesthesia or heavy sedation which means that the dog may have to be left for a short time at the veterinary practice. Hip radiographs can be taken at the same time as those for the BVA/KC Elbow Dysplasia Scheme. When taking the dog for its radiographs owners should remember the following.

- The dog must be at least one year old, but there is no upper age limit.
- The dog must be permanently and uniquely identified by way of a microchip or tattoo.
- The dog's KC registration certificate and any related transfer certificates must be available so that the appropriate details can be printed on the radiographs.
- Microchip/tattoo numbers must also be printed on the radiographs.
- The owner should sign the declaration (first part) of the certificate, to verify the details are correct and grant permission for publication of the results.

Once the radiographs have been taken, the veterinary surgeon must fill out the appropriate section of the certificate and submit both the radiographs and the certificate and the current fee to the BVA.

The results and the radiographs are normally returned to the veterinary surgeon within two weeks with the completed certificate for the owner and a copy for the veterinary surgeon. Once a score has been given for a dog, the radiographs cannot be resubmitted. New radiographs can also not be submitted; however, owners have the right to an appeal which takes the form of a re-appraisal of the original radiographs. A letter of appeal must be made within 45 days of the date of the original certificate. The whole process from initial appointment to receiving the scores is handled through the submitting veterinary surgeon.

The Kennel Club have developed Estimated Breeding Values, or EBVs, a resource that allows breeders to estimate a dog's genetic risk of developing either hip or elbow dysplasia. For more information, please visit [www.mateselect.org.uk](http://www.mateselect.org.uk).



There is a reduced fee when radiographs of the same dog are submitted simultaneously to the CHS for the Hip and Elbow Dysplasia Schemes.

#### For current fees and further information please contact:

**Canine Health Schemes**  
7 Mansfield Street  
London W1G 9NQ  
Telephone 020 7908 6380  
Email [chs@bva.co.uk](mailto:chs@bva.co.uk)  
[www.bva.co.uk/chs](http://www.bva.co.uk/chs)

**The Kennel Club**  
10 Clarges Street  
London W1J 8AB  
Telephone 0844 4633 980  
[hbs@thekennelclub.org.uk](mailto:hbs@thekennelclub.org.uk)  
[www.thekennelclub.org.uk/doghealth](http://www.thekennelclub.org.uk/doghealth)